

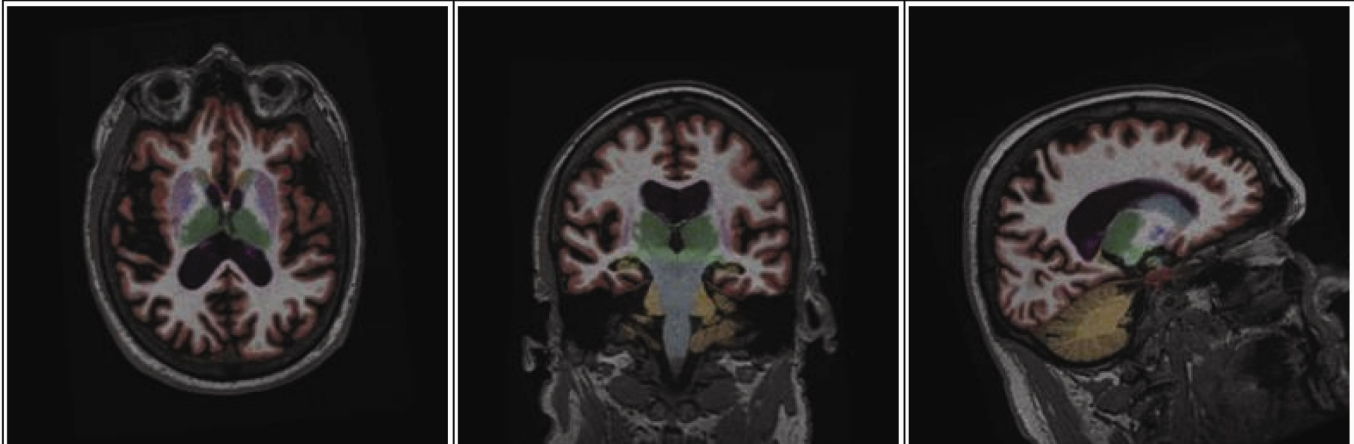
NeuroQuant[®]

General Morphometry Report

PATIENT INFORMATION

Patient ID: 005_S_0221	Patient Name: Smith, John Jr.	Sex: M
Accession Number: 093951-1	Referring Physician: Jones, Steven MD,PhD	Exam Date: 2006/02/22 12:00:00 AM

MORPHOMETRY RESULTS



Brain Structure	LH Volume (cm ³)	LH Volume (% of ICV)	RH Volume (cm ³)	RH Volume (% of ICV)	Asymmetry Index (%) [*]
Forebrain Parenchyma	520.22	31.02	491.11	29.28	5.76
Cortical Gray Matter	264.68	15.78	237.58	14.16	10.79
Lateral Ventricle	25.11	1.50	31.11	1.85	-21.34
Inferior Lateral Ventricle	2.31	0.14	2.53	0.15	-9.09
Hippocampus	2.81	0.17	3.12	0.19	-10.25
Amygdala	1.02	0.06	1.28	0.08	-22.72
Caudate	3.83	0.23	3.79	0.23	1.10
Putamen	4.67	0.28	4.41	0.26	5.59
Pallidum	0.89	0.05	0.85	0.05	4.60
Thalamus	8.72	0.52	8.12	0.48	7.09
Cerebellum	58.25	3.47	57.61	3.44	1.10

^{*}The Asymmetry Index is defined as the difference between left and right volumes divided by their mean (in percent)